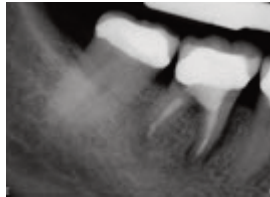




Dr. ELIE M. WOLFSON DENTISTRY
PROFESSIONAL CORPORATION
Certified Specialist in Endodontics



Dear Mrs. Zz,

Thank you for your recent submission regarding your tooth #4.6 (30 - lower right first molar). After reviewing the pertinent medical and dental history the following findings and recommendations are suggested:

- The previous root canal treatment and surgery have healed well post-operatively
- There is a new significant loss of bone on the mesial (front facing) surface of the root that coincides with the swelling you noted in your gum tissues

The above information is highly suggestive of vertical root fracture of the mesial root. This diagnosis can be possibly confirmed by physical examination of the tooth or by surgical exposure of the area and exploration. If the diagnosis is confirmed, it is likely that extraction of the tooth will be needed with consideration of replacement of the tooth.

Once again thank you for the opportunity to examine your records and suggest a diagnosis and treatment. If there are any other questions or issues that require clarification, please contact us again.

Sincerely yours,

EMW